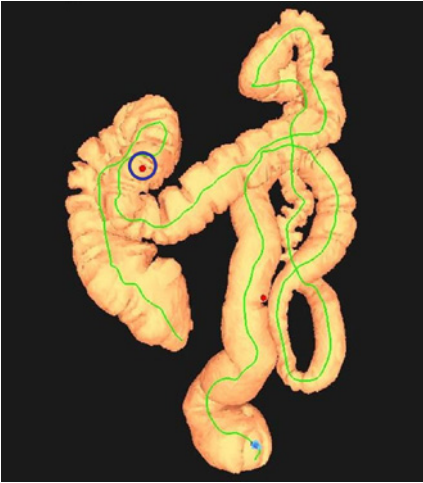

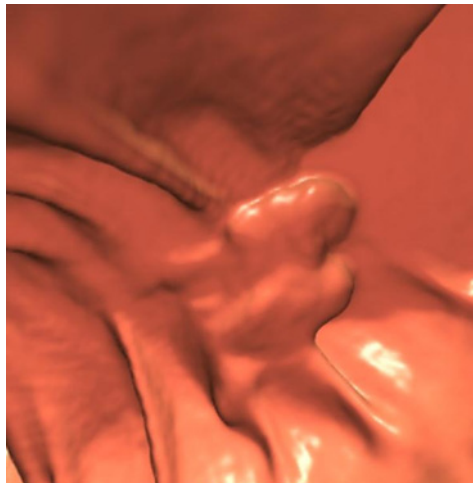
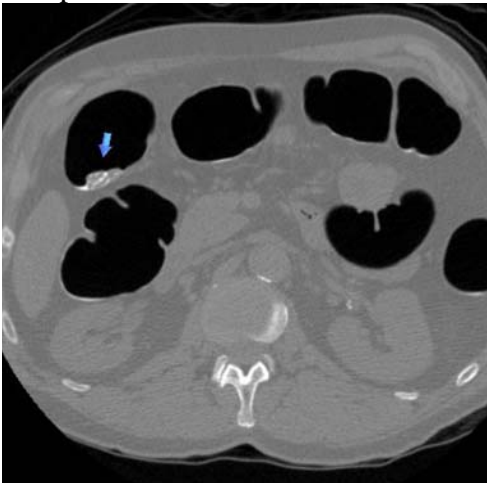
Case 3622

MAP:

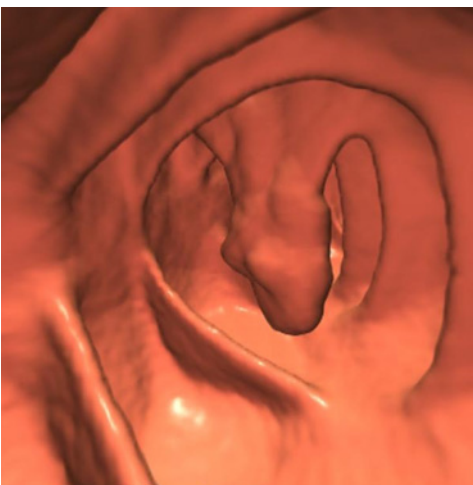
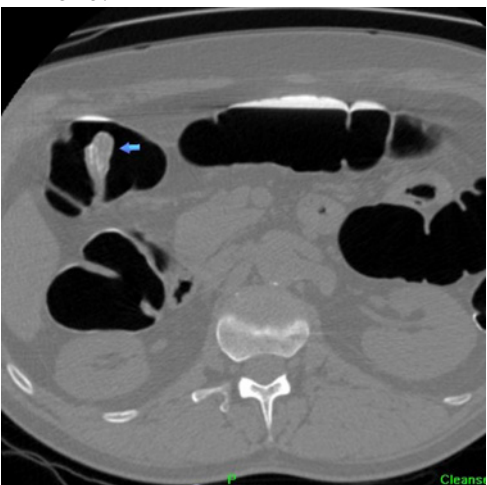


● Hepatic Flexure 35mm SA villous with HGD

Supine:

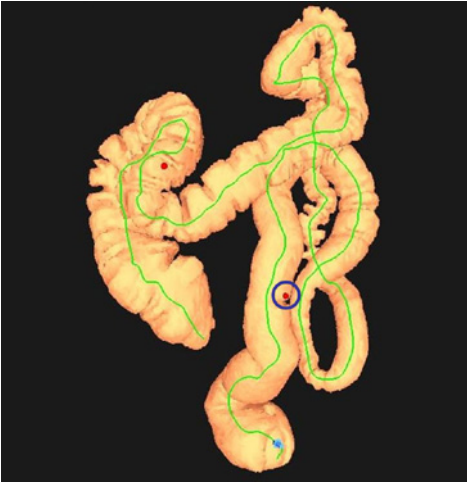


Prone:



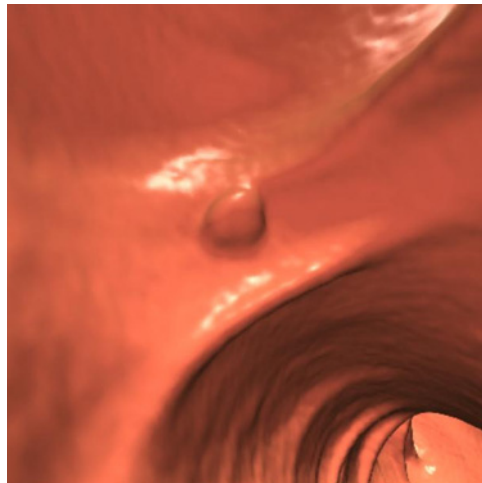
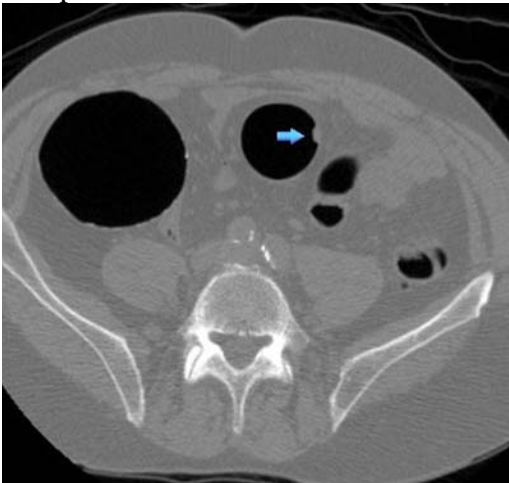Case 3622

MAP:

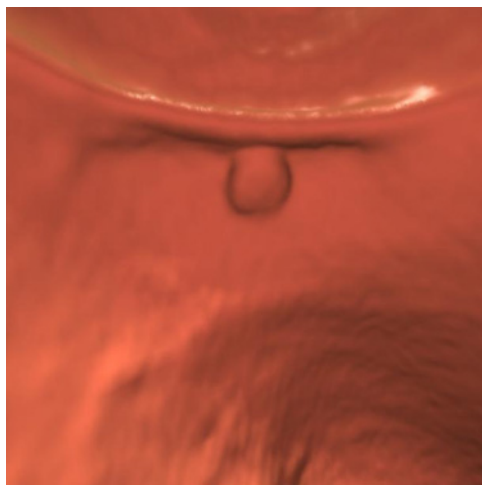
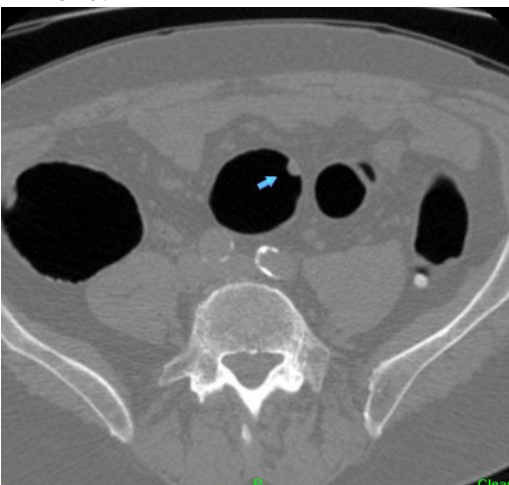


● Rectosigmoid 8mm HP

Supine:



Prone:



Case 3622

PROCEDURE: 45385 - Colonoscopy w/Snare

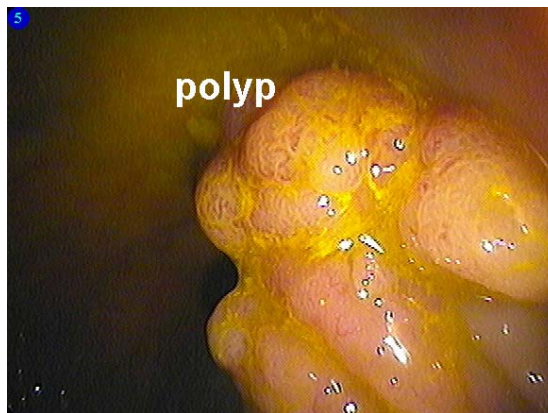
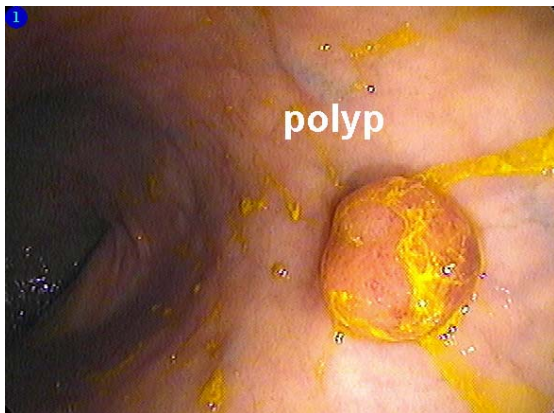
INDICATIONS: colon polyp seen on virtual colonoscopy

MEDICATION: Fentanyl micrograms IV, Midazolam mg IV

DESCRIPTION OF PROCEDURE: The risks, benefits and alternatives of the procedure were discussed. The patient understands and consents. Digital rectal exam was performed and revealed no abnormalities. The EC-3872LK endoscope was introduced through the anus and advanced to the ascending colon. The quality of the prep was excellent. The instrument was then slowly withdrawn as the colon was fully examined.

A sessile polyp was found in the rectum. It was 10 mm in size. Polyp was snared, then cauterized with monopolar cautery. Polyp was retrieved sent to pathology. At the area of the hepatic flexure a large sessile 4 cm polyp was seen. This was removed with piecemeal snare resection. The post-polypectomy appearance was good with no definitive residual polypoid areas seen. The area just adjacent was tattooed with india ink. Retroflexion was not performed. The scope was then completely withdrawn from the patient and the procedure terminated.

IMAGES:



IMMEDIATE COMPLICATIONS: None

ENDOSCOPIC IMPRESSION: 1) 10 mm sessile polyp in the rectum
2) 4 cm hepatic flexure polyp

RECOMMENDATIONS: 1) await biopsy results

REPEAT EXAM: Given size and sessile nature of larger polyp will repeat colonoscopy in 2-3 months to ensure adequate resection

Case 3622